

## Background

Fitting scleral lenses on eyes that have horizontal nystagmus can be technically difficult. Measuring a fast-moving eye is challenging. Therefore, the measurement speed should be as high as possible. Two nystagmus cases are shown in this report showing with the rule astigmatism, extending from the cornea into the sclera. Studies show that nystagmus patients often have high WTR astigmatism<sup>1</sup>.

The advantages of fitting these patients with a scleral lens are more stable vision due to the non-moving nature of the scleral lens as well as a larger optical zone compared to corneal and soft contact lenses.

It is worthwhile considering scleral lenses for patients who have infantile or acquired nystagmus if the underlying condition/etiology cannot be addressed. It is a safe treatment option for patients who are usually left with little or no hope for improvement and for whom mild symptom relief is often appreciated.

## Method

Profilometry was used for the measurements. In these cases the Eye Surface Profiler (ESP) was used, a corneo-scleral topographer. The ESP has 2 projectors, flashing light on the ocular surface each from a different angle (Fig 1). At that moment a single shot image is captured having enough speed to take scans of nystagmus eyes.

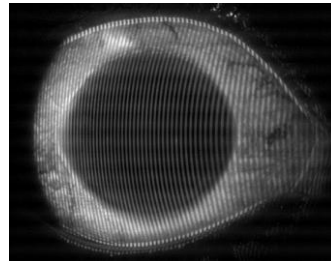


Fig 1 Eye Surface Profiler Grid map

The data information is then transformed into sagittal height data creating a bisphere elevation map.

## Case description

**Case 1** A female albino, with nystagmus 11-year-old patient. She had a number of vision related complaints associated with albinism, including significant nystagmus in both eyes blurred vision (VA 6/36 N24) and photophobia

**Case 2** 25-year-old male, diagnosed with nystagmus, binocular amblyopia and a high corneal astigmatism following the rule continuing into the sclera.

## Results

### Case 1

Profilometry measurements taken with the Eye Surface Profiler (Eaglet Eye, the Netherlands) revealed a cornea and sclera showing a high-toric eye “with the rule”. The sagittal height difference at a 13mm chord was 290 microns and at a 15mm chord was 350 microns showing WTR astigmatism (Fig 2).

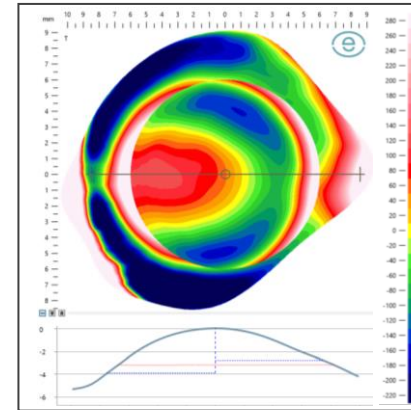


Fig 2 ESP Bisphere elevation map

Due to the high astigmatism, it was decided to fit the patient with a freeform lens. Profilometry data driven MAXIM 3D scleral lens (AccuLens, USA) was decided to be the best option for this patient. The initial lenses dispensed were the final lenses (Fig 3):

OD BC 7.85 SAG 4420 Dia. 15.9mm  
OS BC 7.50 SAG 4730 Dia. 15.9mm

Resulting in good fitting, comfortable first pair of lenses giving the patient ‘happy’ VA of 6/6 N8.

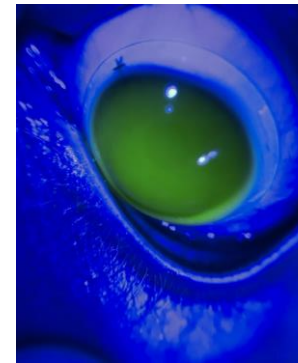


Fig 3 First Fit AccuLens MAXIM 3D

### Case 2

Profilometry revealed with the rule toricity of 450 microns at 13mm and 790 at 16mm chord, a large difference between the 13mm and 16mm chord length of 340 microns (Fig 4).

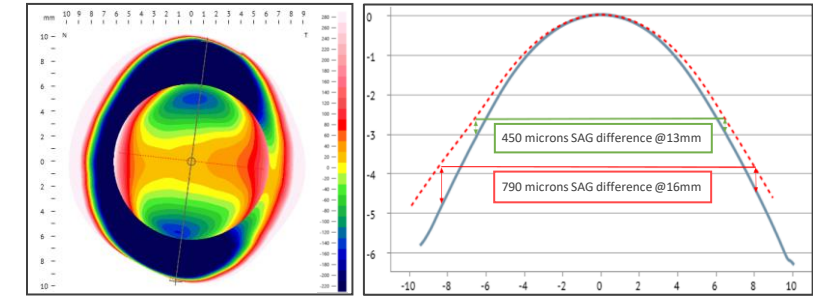


Fig 4 Bisphere Elevation map

The scleral lens ordered was a 16 mm Bi-Elevation Zenlens (ZenBE) (Bausch+Lomb, USA) design. Being able to add toricity to the landing and limbal zone we can predict that the lens will align better:

BC 9.13 SAG1/SAG2 4100/4550 S+1.00 Flat3/Steep5.

The adjustment made using the bi-sphere elevation map resulted in a much better alignment and centration of the scleral lens (Fig 5), increasing the comfort. When the patient came back for the follow up, the comfort and the vision of the lenses was good, and no changes needed to be made.

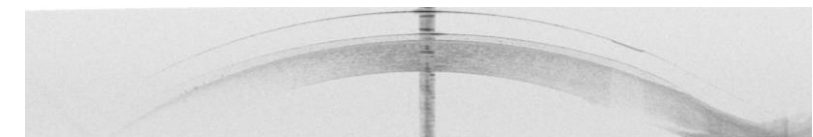


Fig 5 OCT image

## Conclusion

Both nystagmus patients were fit with scleral lenses based on Profilometry data. The fast Fourier transformation based, single shot profilometer allows for good measurements even on patients with nystagmus. Both patients showed toricity with the rule. The toricity increases as the chord length increases. As a result, the scleral lens approach for both these patients was the best approach. Could it be that the hyperactive extraocular muscle does induce flattening of the horizontal meridian?

<sup>1</sup> CornealTopographyofHumansWithCongenitalNystagmus1984.pdf